

## Intracranial Hemorrhage Associated with Biliary Atresia

**Chafi S\***

*Pediatric Consultant, Pediatrics Service, Public Hospital of Bordj Bounaama Tissemsilt, Algeria*

**\*Corresponding Author:** Chafi S, Pediatrics Consultant, Pediatrics Service, Public Hospital of Bordj Bounaama Tissemsilt, Algeria.

**Received:** July 18, 2022; **Published:** August 30, 2022

### Abstract

Biliary atresia (BA) is a rare disease characterized by biliary obstruction in which the etiology remains obscure. In this report we describe a case of 40 days old female child fully breastfed that had not received vitamin K prophylaxis after birth. The latter presented to paediatric emergency department with severe jaundice, abnormal neurological exam and hepatomegaly, head CT scan was suggestive of massive left temporal intra parenchymatous and sub-Arachnoid hemorrhage related to vitamin k deficiency, neonatal cholestasis has been found to be related to biliary atresia which has led to vitamin k deficiency. After the enfant has recovered neurologically he has been referred to paediatric surgery team where a Kasai Portoenterostomy procedure has been done timely. Thus biliary atresia should be considered in all patients with cholestasis because early diagnosis could prevent severe complications and results in a better prognosis.

**Keywords:** *Biliary Atresia; Intracranial Hemorrhage; Vitamin K Deficiency; Kasai Portoenterostomy; Neonatal Cholestasis*

### Abbreviations

BA: Biliary Atresia; CT Scan: Computed Tomography Scan; MRI: Magnetic Resonance Imaging; MRC: magnetic resonance cholangiography; PT: Prothrombin Time; aPTT: Activated Partial Thromboplastin Time

### Introduction

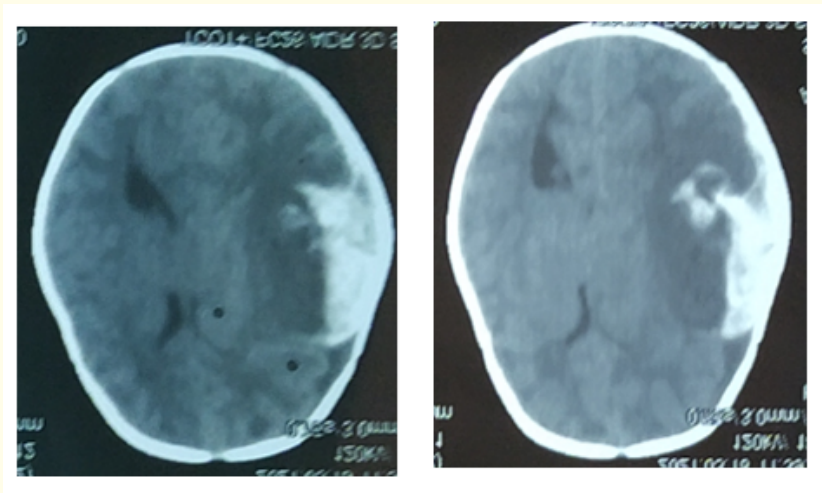
Biliary atresia (BA) is the most frequent identifiable cause of neonatal cholestasis, histopathologically, the main feature is that of inflammation and damage to the intra-and extrahepatic bile ducts untreated it leads to hepatic cirrhosis and high mortality within the first years of life. Treatment consist in restoring bile flow with Kasai Portoenterostomy.

Vitamin k deficiency and consequent impaired coagulation in cholestasis is the result of reduced bile flow and malabsorption of fat soluble vitamins, it manifests usually late in the course of the disease and can lead to severe bleeding amongst them intracranial hemorrhage. In our case vitamin k deficiency was the reason of severe intracranial bleeding which could be preventable if the diagnosis and management were earlier with appropriate supplementation of vitamin K.


### Case Report

We present a case of 40 days old girl of non-consanguineous marriage at full term with a birth weight of 3 kg, fully breastfed delivered vaginally without any specific medical history apart from non-receiving Vitamin K prophylaxis after birth she presented to the emergency

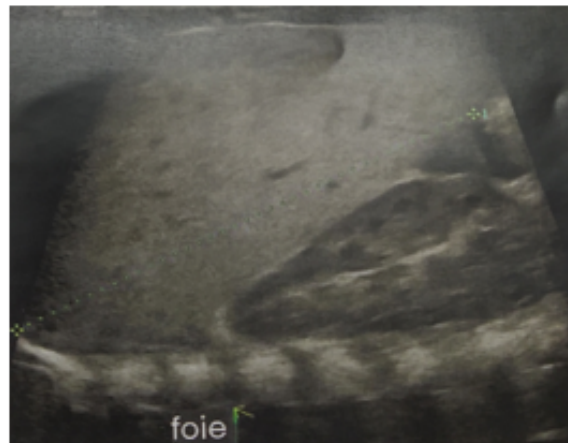
department for sudden altered consciousness. On examination she was afebrile, heart rate was at 110, capillary refill time was 2 seconds, she had pallor and severe jaundice, neurological examination was abnormal with bulging anterior fontanelle, hypotonia, anisocoria, otherwise hepatomegaly and pale stools have been noticed, the patient weighed 3.8 kg. Biochemical exploration revealed: anemia at 7,7 mg/dl, white cell count of 12000/cumm, platelets of 3,89000/cumm, high total bilirubin (80 umol/l) rate with more than 20% direct bilirubin (25,3 umol/l), liver function test was perturbed with high ASAT (125 u/l), ALAT (96) and gamma GT (193). Prothrombin time was prolonged and partial thromboplastin time was normal, Serum electrolytes, urea and creatinine were normal. Cerebral CT-scan revealed left temporal intra-Parenchymatous and sub arachnoid hemorrhage with mass effect. After neurological stabilization of the patient with supportive measures (Oxygenation, head-of-bed elevation, vitamin K, fresh frozen plasma and hydrocortisone) an abdominal ultrasound with Doppler was done which showed hepatomegaly with normal texture associated to rudimentary gallbladder, the patient was referred to Paediatric gastroenterology service where the diagnosis of biliary atresia was confirmed with cholangiography-MRI after eliminating other causes of cholestasis. The patient has been oriented to Paediatric surgical team, there, the patient underwent a successful Kasai Hepato-Porto-Enterostomy at the age of 2 months. Seen after 6 months, the patient has improved, hepatomegaly and jaundice have completely disappeared, with normal biological analysis.



**Figure 1:** A-B intracranial bleeding with mass effect.



**Figure 2:** Shows rudimentary gallbladder.



**Figure 3:** Shows hepatomegaly.

### Discussion

Vitamin K levels are low at birth and exclusively breastfed infants are at much higher risk of presenting with vitamin K deficiency. According to Algerian guidelines, receiving vitamin K after birth is mandatory to prevent the hemorrhagic disease of the newborn, in the form of oral drops at the dose of 2 mg or 1 mg intramuscular; cholestasis is considered one of the main causes of hemorrhage disease of the newborn due to vitamin K deficiency. However this was reported most in infants which had not received vitamin k prophylaxis. The patient discussed in this article was exclusively breastfed and had missed his vitamin K prophylaxis after birth, intracranial bleeding in this case was found to be secondary to vitamin k deficiency as a consequence of an extra-hepatic bile duct atresia. Since vitamin K is a fat-soluble vitamin, its deficit decreases the vitamin K dependent coagulation factors (II, VII, IX, X). Coagulation studies revealed reduced activity in factors from the extrinsic pathway (factor VII), which resulted in a prolonged PT, whereas aPTT which reflect the factor IX activity was normal.

Neonatal cholestasis is a failure of bilirubin secretion resulting in hyperbilirubinemia and jaundice that persists beyond the first 2 weeks of life. It commonly presents with icterus, hepatomegaly and alcoholic stools. There are several causes of neonatal cholestasis, including infectious, genetic and metabolic diseases. However, biliary atresia is the main identifiable reason that should be diagnosed and treated timely to ensure a better prognosis, The incidence of biliary atresia varies from about 1: 5,000 live births in Taiwan to lower rate of 1 to 5 in 20,000 in England and wales, slight female predominance and seasonal variability have also been reported. The classical clinical triad of biliary atresia after birth consists of jaundice, alcoholic stools and hepatomegaly. With the progression of the disease signs of liver cirrhosis, splenomegaly, ascites, signs of portal hypertension and failure to thrive occur.

The patient discussed in this report presented with the classical triad of cholestasis which had not been noticed by her parents before admission. Swift diagnosis is primordial and is as important for etiological management as for preventing complications related to cholestasis. in our case intracranial hemorrhage could have been prevented by appropriate supplementation with vitamin k if early screening and diagnosis have been done timely, however despite of relatively late diagnosis the patient has recovered completely neurologically with vitamin K an fresh frozen plasma administration, moreover Kasai Portoenterostomy procedure was successful at 2 months of age.

The North American Society for Pediatric Gastroenterology, Hepatology and Nutrition (NASPGHAN) recommends that primary care providers screen for cholestasis in any infant that is jaundiced  $\geq$  the age of 2 weeks. It is recommended to perform laboratory studies to assess hepatobiliary function, abdominal ultrasound is non-invasive test which is performed as an initial exploration in cholestasis however it cannot exclude biliary atresia alone, hepatobiliary scintigraphy may be useful in differentiating biliary atresia from other causes of cholestasis. If the biliary atresia remains suspect in spite of the all these investigations, per-operative cholangiography, should be performed to confirm or rule out the diagnosis. According to the NASPGHAN there is no superior investigation in its self for the diagnosis of neonatal cholestasis. The main aim is to recognize this condition and have the reflex to refer the patient as soon as possible to a pediatric gastroenterologist for appropriate management.

In our case hepatobiliary scintigraphy was not available, magnetic resonance cholangiography (MRC) was an alternative. According to a study conducted by Seok Joon Han and all in Seoul the diagnosis of biliary atresia was made by MRC based on the non-visualisation of extrahepatic bile ducts in light of this study and others MRC is a reliable noninvasive imaging modality for the diagnosis of biliary atresia, and could avoid unnecessary surgery [1-20].

### Conclusion

Although rare and obstinate, BA should be considered in the treatment of intracranial hemorrhage due to vitamin K deficiency, since it is reported to be one of the major causes of secondary vitamin K deficiency. Although it is crucial to early diagnose biliary atresia this should be after stabilizing a life threatening complication. Finally early diagnosis of neonatal cholestasis in particular biliary atresia reduces significantly the morbidity and mortality therefore emphasis should be put on new strategies of neonatal screening.

### Bibliography

1. Liesbeth Claire Faverey and Yvan Vandenplas. "Hemorrhagic Diathesis as the Presenting Symptom of Neonatal Cholestasis". *Pediatric Gastroenterology, Hepatology and Nutrition* 17.3 (2014): 191-195.
2. Petersen C and Davenport M. "Aetiology of biliary atresia: what is actually known?" *Orphanet Journal of Rare Diseases* 8 (2013): 128.
3. Miyao M., et al. "Subdural hemorrhage: A unique case involving secondary vitamin K deficiency bleeding due to biliary atresia". *Forensic Science International* 221 (2012): e25-e29.
4. Ijland MM., et al. "Incidence of late vitamin K deficiency bleeding in newborns in the Netherlands in 2005: evaluation of the current guideline". *European Journal of Pediatrics* 167 (2008): 165-169.
5. Chardot C. "Biliary atresia". *Orphanet Journal of Rare Diseases* 1 (2006): 28.
6. Hussein A., et al. "Kasai portoenterostomy: new insights from hepatic morphology". *Journal of Pediatric Surgery* 40 (2005): 322-326.
7. Tang ST., et al. "Diagnosis and treatment of biliary atresia: a retrospective study". *Hepatobiliary and Pancreatic Diseases International* 4 (2005): 108-112.
8. Uchida K., et al. "Predicting factor of quality of life in long-term jaundice-free survivors after the Kasai operation". *Journal of Pediatric Surgery* 39 (2004): 1040-1044.
9. Moyer V., et al. "North American Society for Pediatric Gastroenterology, Hepatology and Nutrition. Guideline for the evaluation of cholestatic jaundice in infants: recommendations of the North American Society for Pediatric Gastroenterology, Hepatology and Nutrition". *Journal of Pediatric Gastroenterology and Nutrition* 39 (2004): 115-128.

10. Roberts EA. "Neonatal hepatitis syndrome". *Seminars in Neonatology* 8 (2003): 357-374.
11. McKiernan PJ. "Neonatal cholestasis". *Seminars in Neonatology* 7 (2002): 153-165.
12. Schlesinger AE., et al. "Hepatobiliary system". In Kuhn JP, Slovis TL, Haller JO (editions): *Pediatric Diagnostic Imaging*, edition 10. St. Louis, Mosby (2004): 1445-1517.
13. Dellert S and Balistreri W. "Chapter 52 - Neonatal Cholestasis". In: Walker W, Durie P, Hamilton J., et al. "Pediatric Gastrointestinal Disease, third edition. Lewiston, NY: B.C. Decker Inc (2000): 880-891.
14. Sato H., et al. "Intracranial hemorrhage due to vitamin K deficiency associated with congenital biliary atresia: a case report". *Neurosurgical Emergencies* 5 (2000): 77-80.
15. Fischler B., et al. "The viral association of neonatal cholestasis in Sweden: a possible link between cytomegalovirus infection and extrahepatic biliary atresia". *Journal of Pediatric Gastroenterology and Nutrition* 27 (1998): 57-64.
16. Van Den Anker JN and Sinaasappel M. "Bleeding as presenting symptom of cholestasis". *Journal of Perinatology* 13 (1993): 322-324.
17. Chang MH., et al. "Polymerase chain reaction to detect human cytomegalovirus in livers of infants with neonatal hepatitis". *Gastroenterology* 103 (1992): 1022-1025.
18. Ryan CA and Gayle M. "Vitamin K deficiency, intracranial hemorrhage, and a subgaleal hematoma: a fatal combination". *Pediatric Emergency Care* 8 (1992): 143-145.
19. Fukuda T., et al. "Intracranial hematoma accompanying bleeding tendency: therapeutic practice and analysis of literature (in Japanese)". *No Shinkei Geka* 18 (1990): 511-520.
20. Chaou WT., et al. "Intracranial hemorrhage and vitamin K deficiency in early infancy". *The Journal of Pediatrics* 105 (1984): 880-884.

**Volume 11 Issue 9 September 2022**

**©All rights reserved by Chafi S.**