

Validity and Reliability of the HipDysplasiaApp to Evaluate Hip Dysplasia. Can We Use it in an Everyday Clinical Setting?

**Nikolaos G Papadimitriou^{1*}, Eleftherios Tiakas², Ioannis Delniotis³, Theofanis Kantas³, Evangelos I Foufloulas³,
Konstantinos Ditsios¹ and Papadopoulos P¹**

¹2nd University Department of Orthopaedics, Aristotle University, Thessaloniki, Greece

²Department of Informatics, Aristotle University, Thessaloniki, Greece

³Department of Orthopaedics, Ippokratia General Hospital, Thessaloniki, Greece

***Corresponding Author:** Nikolaos G Papadimitriou, 2nd University Department of Orthopaedics, Aristotle University, Thessaloniki, Greece.

Received: July 13, 2019; **Published:** September 17, 2019

Abstract

Study Design: This was a prospective blinded validity and reliability analysis.

Objective: The aim of this study was validation and reliability evaluation of the HipDys-plasiaApp.

Methods: Two independent observers performed radiographic measurements of radiographs of 73 patients with developmental dysplasia of the hip. Given the fact that 2 x-rays were measured for each hip of the 73 patients (the first diagnostic X-ray and the one at the end of treatment), a total of 4 hip x-rays were measured for each case, resulting in a total of 292 hips measured by the observers. They measured the Acetabular Index (AI), the Center-Edge (CE), the Acetabular Depth-Width Ratio (ADR), the femoral head extrusion index or Reimer Index (RI), the Congruity Index (CI), the Sharp's angle (SA), Tonnis grade of dislocation (TG), the Acetabular Index of the Weight-Bearing Zone (AIW) and the Congruence Index (CG) of a total of 292 hips using the HipDysplasiaApp. They also performed manual measurements using the classical method on an X-ray viewer. Measurements were performed on an iPhone (Apple) and, for the classic method of measurement, the observers used pencils, a protractor and rulers. The validity, as well as the interobserver and intraobserver reliability, were calculated using the intraclass coefficient (ICC) between the HipDysplasiaApp and the manual measurements.

Results: The intraclass coefficient (ICC) of the intraobserver and interobserver reliability and validity of all indexes (AI, AIWB, CE, RI, ADR, CI, SA, TG, CG) were between 0,994 and 0,999 ($p < 0,001$) for the HipDysplasiaApp. The time needed to measure using the HipDysplasiaApp, when compared with the manual measurements, is significantly shorter (mean time 35 seconds for the HipDysplasiaApp vs 34 - 39 minutes when measured manually).

Conclusion: The intraobserver and interobserver reliability of the Hip dysplasia App, as well as its validity when compared with the manual measurement, is excellent. The application is valid for clinical evaluation. It is a handy tool for an orthopaedic surgeon. By choosing a few points of measurement on the screen of the application, it calculates the whole range of measurements in seconds. The built-in features can compare the results with a reference database. Furthermore, categorization offers a major helping tool in every-day clinical setting. The values are stored and can be used for later evaluation.

Level of Evidence: Level I (Diagnostic Study).

Keywords: Dysplasia; Radiography; X-Ray; Measurement; Classification; Hip; Angle; Index; Smartphone; i-phone App; Applications; Mobile; DDH; Developmental; iPhone app; Smartphone

Introduction

Hip dysplasia leads to premature osteoarthritis [1-4] of the hip and accounts for many total hip replacements in patients. Early diagnosis is extremely important and is based mainly on radiological findings. Correct measurements of indexes [5-7] such as the Ace-tabular Index (AI) [5], the Center-Edge (CE) [8], the Acetabular Depth-Width Ratio (ADR) [9], the femoral head extrusion index or Reimer Index (RI) [4], the Congruity Index (CI) [10,11], the Sharp's angle (SA) [12,13], Tonnis grade of dislocation (TG) [14], the Acetabular Index of the Weight-Bearing Zone (AIW) [15,16] or Horizontal Toit externe angle (HTE), and Congruence Index [17] (CG), are important for a surgeon who wants to objectively assess standard radiographs of the hips. These measurements, usually performed on X-rays by traditional methods, are time-consuming and cumbersome. This is because one has to draw lines with well sharpened pencils and rulers, measure angles with protractors and calculate percentages or ratios over the x rays. Further-more, one has to compare the measured values with databases in reference books and decide on what is pathologic or normal according to gender, age and hip side. Measuring 9 indexes for each hip takes time and effort, which are valuable assets in everyday clinical settings.

The HipDysplasiaApp [18] is an application written for iOS 12 (Apple Inc., Cupertino, CA). It is not a simple goniometer or ruler, but an integration of technology that uses the camera, touch screen, and computational power of the Smartphone or tablet in order to help surgeons quickly measure 9 radiographic indexes for each hip with a few 'clicks'. Results are compared and categorized according to gender, age and side and compared to reference databases for each measured Index. Data are printed or exported in text files with numerical values and also with a suggestive diagnosis.

Aim of the Study

The aim of this study was to compare the validity and reliability of the HipDysplasiaApp in the clinical setting and compare it with classic manual measurements (Figure 1) on an X-ray viewer board. For this purpose, we tested the intraobserver and interobserver reliability of the HipDysplasiaApp and assessed its validity compared to the traditional manual method. We hypothesized that the application will be a valid and reliable instrument that could be used in daily clinical settings even by unexperienced users.




Figure 1: Manual measurements with the classic way over x ray viewer.

Materials and Methods

Patients

The medical records of 73 patients diagnosed with developmental dysplasia of the hip, who had been managed using the Papadimitriou functional method (modified Hoffmann-Daimler method [19-21]) between January 1971 and December 2017 were reviewed. 61 were female and 12 were male patients, with ages ranging from 2 months to 40 years and a mean age of 4.7 ± 7.04 years. All patients displayed developmental dysplasia of the hip, measurable on x-ray.

Two X-rays were assessed for each patient's hip, namely the first diagnostic X-ray and the one at the end of treatment. Given the fact that two x-rays were measured for each hip of the 73 patients, a total of four hip x-rays were measured for each case, resulting in a total of 292 hips measured by two observers. Out of the two observers, one was an experienced orthopaedic surgeon (observer #1) and the other a less experienced orthopaedic surgeon (observer #2). Patients previously operated on, those who were man-aged with open reduction, or those in whom the dislocation of the hip was secondary to neuromuscular disease, arthrogryposis, septic arthritis, a teratological condition or associated with a congenital anomaly or syndrome were excluded from the study. This study was approved by the local ethics committee.

Methods

Manual measurements

The classic way of measurement (Manual Measurement-MM) consisted of the measurement of all hip dysplasia Indexes (AI, CE, ADR, RI, CI, SA, TG, AIW, HTE and CG) using the patients' X-rays over the X-ray viewer. Protractors, rulers, pencils and transparent paper are used to draw and calculate all these Indexes manually (Figure 1). In order to have an idea of what is pathologic and what is normal out of the measured values, every value has been compared with reference-specific databases for age, gender and side by the user in order to evaluate the result as objectively as possible. In our study we don't use the lateral sourcil for measurement of the indexes in which the lateral acetabular margin is implicated, but use the classic methods making use of the lateral margin of the acetabulum instead [22].

Measurement using the "HipDysplasiaApp"

The electronic measurements were made using the "HipDysplasiaApp" application [18], version 2.0 (copyright orthopractis.com [23]), installed on iPhone X (Apple Inc.) running on iOS 12 [18]. The method of measuring with the app is demonstrated on video 1. The patient's X-rays are imported in the application using the camera or stored photos. After inserting the patient's gender and age, the user marks five points P1-P5 on the same X-ray, at each hip. The built-in transparent circular template appears (Moses template), which consists of several concentric circles. The user aims to position the center of the femoral head by moving the template over the femoral head, trying to fit a best-fit circle to the contour of the femoral head circumference. Once one finds the best-fitted circle superimposed over the femoral head, one clicks the 'point' button, which marks the center of the femoral head; the first point of measurement is marked (P1). After that, a dynamic red circle appears with the P1 center point marked over the screen. The radius of the circle is changed dynamically by finger movement, and the user tries to find the best fit circle to the contour of the femoral head circumference. Once the best fit is found, the user presses the "point" button and the whole femoral head is marked with a blue circle (P2). Next, the user aims at the lateral acetabular border and by pressing the "point" button, the P3 point is marked. Similarly, one aims at the juncture of the triradiate cartilage of the acetabulum and marks the P4 point. In case the patient is over 7 years of age, the triradiate acetabular cartilage is ossified and one has to choose the most medial edge of the weight bearing surface of the acetabulum. The weight-bearing portion of the acetabulum is recognised by its sclerotic, arched appearance, resembling an eyebrow (sourcil). Finally, the user aims at the last point, the tear drop of the acetabulum, and by pressing again the "point" button the P5 point is marked. The application calculates the 9 above mentioned indexes (AI, AIWB, CE, RI, ADR, CI, SA, TG, CG) automatically. Built-in gender, age and side-specific normal reference databases are used and, in cases where values are out of normal ranges, the hip is categorized according to the measured Index normal categorization. All numerical data are printed over the image or exported as text file for each hip separately and the respective categorization for each hip variable.

The above mentioned 9 radiographic indexes for hip dysplasia were also measured by each observer manually over the X-ray Film viewer with the use of a calculator to help calculate ratios and percentages.

The duration of measurement for each observer for the application measurement (OBS#1) and the manual measurement (OBS#2) were recorded.

The Application offers a very convenient way to determine the 9 above mentioned indexes of hip dysplasia in the most accurate way possible. By inserting the patient’s gen-der, age and the 5 marking points at the same X-ray for each hip, the application calculates the nine above mentioned indexes (AI, AIWB, CE, RI, ADR, CI, SA, TG, CG) with-out having to repeat each measurement separately. All radiographic indexes are measured in one picture. Gender, age and side-specific normal reference databases are used and in cases where values are out of normal ranges, the hips are categorized accordingly.

We decided to test the validity and reliability of the HipDysplasiaApp application using an iPhone. Two observers were asked to measure the indexes (AI, AIWB, CE, RI, ADR, CI, SA, TG, CG) for all patients involved in this study. The observers consisted of an experienced paediatric orthopaedic surgeon (observer #1) and one senior resident in the orthopaedic department (observer #2,) who acted as the inexperienced observer. Measurement of the hip dysplasia indexes was performed with the Hip dysplasia application as well as manually with the method described above (Figure 2). To minimize bias, observers were blinded to one another. To assess the interobserver reliability of each Index, all of them were measured using the iPhone by the two observers.

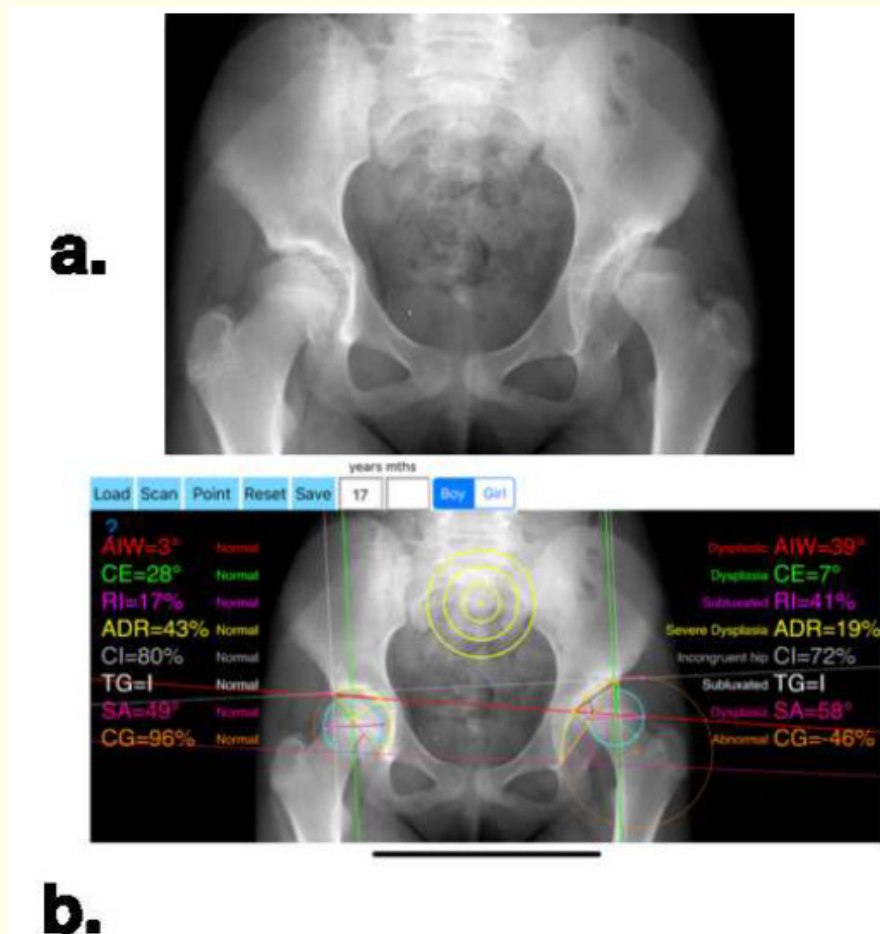


Figure 2: a. Pelvic x ray of a 17-year old female patient with a left dysplastic hip. b. Measurements on the HipDysplasiaApp. Acetabular Index (AI), the Center-Edge (CE), the Acetabular Depth-Width Ratio (ADR), the femoral head extrusion index or Reimer Index (RI), the Congruity Index (CI), the Sharp’s angle (SA), the Tonnis grade of dislocation (TG), the Acetabular Index of the Weight-Bearing Zone (AIW) or Horizontal Toit externe angle (HTE) and the Congruence Index (CG) are measured. Indexes are depicted for both left and right hip and categorized according to age and gender after comparison with normal reference data.

Statistical analysis

The intraclass coefficient (ICC) was used to assess the intraobserver and interobserver reliability and validity. Data were analysed with SPSS (ver.25). For the intraobserver re-liability, the two measurements made by the experienced orthopaedic surgeon (observer #1) with the iPhone were compared for each Index. The ICC for the interobserver reliability was obtained with the manual measurements made by observer #2, and the mean of the iPhone measurements taken by observer #1. The ICC of the HipDysplasiaApp validity was obtained using the mean of the iPhone measurements of observer #1 and the values obtained from the manual measurement made by observer #2. An ICC greater than 0.75 is considered good, over 0.85 very good, and over 0.9 excellent. The standard Error of Measurement (SEM) was also calculated ($SEM=SD * (\text{square-root}(1-ICC))$) for all Indexes [24,25]. The intraclass coefficient (ICC) of the intraobserver and interobserver reliability and validity for each of the above mentioned indexes (AI, AIWB, CE, RI, ADR, CI, SA, TG, CG) were calculated.

Results

The two observers performed the assessment of the Hip Dysplasia Indexes using the HipDysplasiaApp on a total of 73 patients. Assessing 2 X-rays on each patient, 4 hips per patient have been assessed, resulting in a total of 292 measurements.

The mean value, the SD and ICC value (intraobserver and interobserver reliability and validity) with SEM of the indexes (AI,CE,RI) measured with the HipDysplasiaApp by OBS#1 and also the mean value of the indexes the SD and ICC value (intraobserver and interobserver reliability and validity) with SEM measured by OBS#2, are presented in table 1 respectively.

	OB#1 try1	SD	OB#1 try2	SD	OB#2 try 1 manual	SD	Intra-observer Reliability	SEM (standard error of measurement)	P	Interobserver Reliability	SEM (standard error of measurement)	P	Validity	SEM (standard error of measurement)	P
AI degrees	26.36	13.60	26.42	13.97	26.82	13.842	0,994	2,13	<0.01	0,991	2,60	< 0,01	0,992	2,45	<0.01
CE degrees	-.70	34.13	-0.45	34	-.38	34.99	0,998	3,04	<0.01	0,998	6,91	< 0,01	0,998	6,90	<0.01
Reimer Index %	57,90	64,04	56,8	62.7	57	63,19	0,998	5,63	<0.01	0,998	12,70	< 0,01	0,999	12,60	<0.01

Table 1: Data on intraclass correlation coefficient (ICC) for interobserver and intraobserver reliability and validity and SEM (standard error of measurement for HipDysplasiaApp Obs#1 and Manual measurement Obs#2, for AI, CE, Reimer Index radiographic measurements.

Although we measured the rest of the Indexes too, for simplicity reasons and for the article’s benefit we do not present the ICC for the Indexes which were around 0,995 to 0,999.

The duration of measurement for each observer in seconds or minutes for the OBS#1 of the HipDysplasiaApp and the OBS#2 for the manual measurements were also calculated. The mean duration of measuring a single X-ray of two hips for the OBS#1 was 35.2 seconds (SD 6.5, range 22 - 66 seconds). The mean time of Obs#2 was 34.6 minutes (SD 6.7, range 29 - 50 minutes) ($p < 0.00001$).

Discussion

This study demonstrated the validity of the “HipDysplasiaApp” application on the iPhone or iPad in a clinical setting by measuring nine Hip Dysplasia Indexes. On the basis of intraobserver and interobserver reliability, we show here that the manual measurement and the measurements with the Hip Dysplasia App are equivalent for measuring all these Indexes. Our study validated the use of the HipDysplasiaApp application as excellent (ICC = 0.999, $p < 0.001$). The study clearly shows that the application is a valid instrument to measure hip Dysplasia Indexes on patients’ X-rays. Considering the calculated ICC of 0.99, there is an excellent correlation between the HipDysplasiaApp application measurement and the manual measurements. We believe that the application is better than the manual method of measurement mainly because of the time needed. The mean difference of duration of time to measure with the HipDysplasiaApp when compared with manual measurements, is striking (mean time: 35 seconds for the application versus 34 minutes for the manual measurement).

We have also seen an excellent ICC of 0.995 ($P < 0.001$) between the two observers, the experienced (observer #1) and the non-experienced (observer #2). These data show that irrespective of the experience of the observer, the correlation is excellent and we can confirm that measures taken by the application can be used as a tool for evaluating dysplastic hips even by non-experienced physicians. This could be explained by the fact that the App is independent from errors produced by image inclination. Build-in developed modules allow the user to measure accurately without the need to worry about the tilting of the picture or the X-ray. Furthermore, the built-in transparent circular template allows identification of the points of interest such as the center of the femoral head, the lateral acetabular edge or the lateral margin of the teardrop easier. These can be marked in a reproducible way, independently of the experience of the user. The numerical data (Figure 3 and 4) calculated by the HipDysplasiaApp and displayed on the smartphone’s screen, do not require further interpretation. When using manual measurements, these measurements must be evaluated by seeking normal reference values in textbooks or medical journals, before the examiner has to compare them according to age, gender and side values with the normal references. This particular built-in feature of the HipDysplasiaApp with the originally preloaded reference database for each Index saves the user an enormous amount of time, as the measured data is automatically compared and categorized according to age, gender and side of the patient. The results are showed on the screen, printed and/or exported as a text file. The data can be stored for future evaluation, patient follow-up or research.

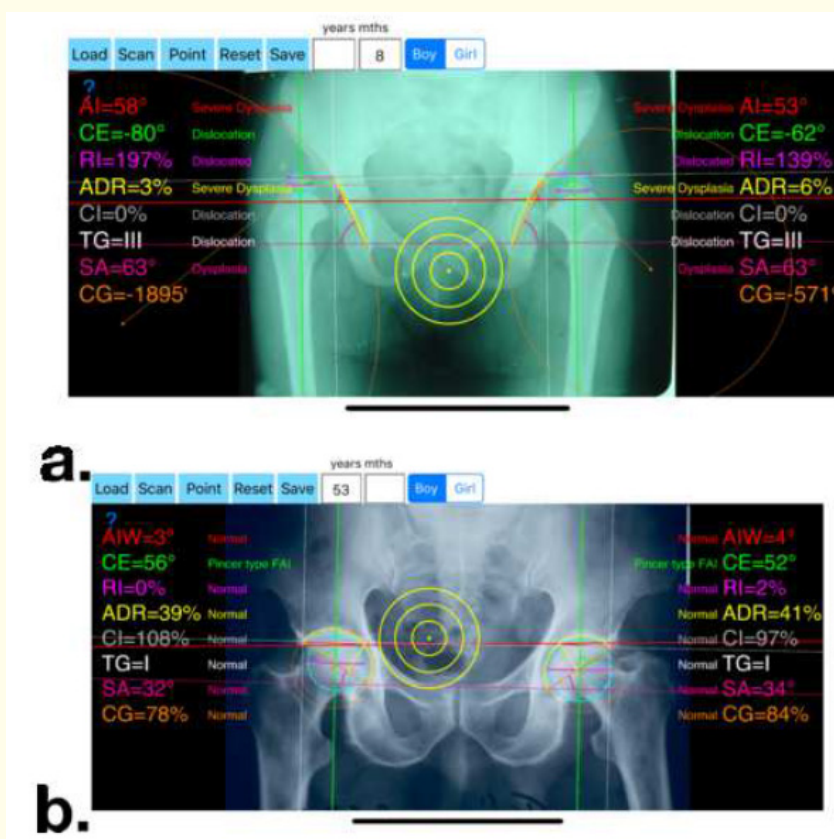


Figure 3: Radiographic Indexes calculated with the HipDysplasiaApp. a. At 32 months of age. b. At older age.

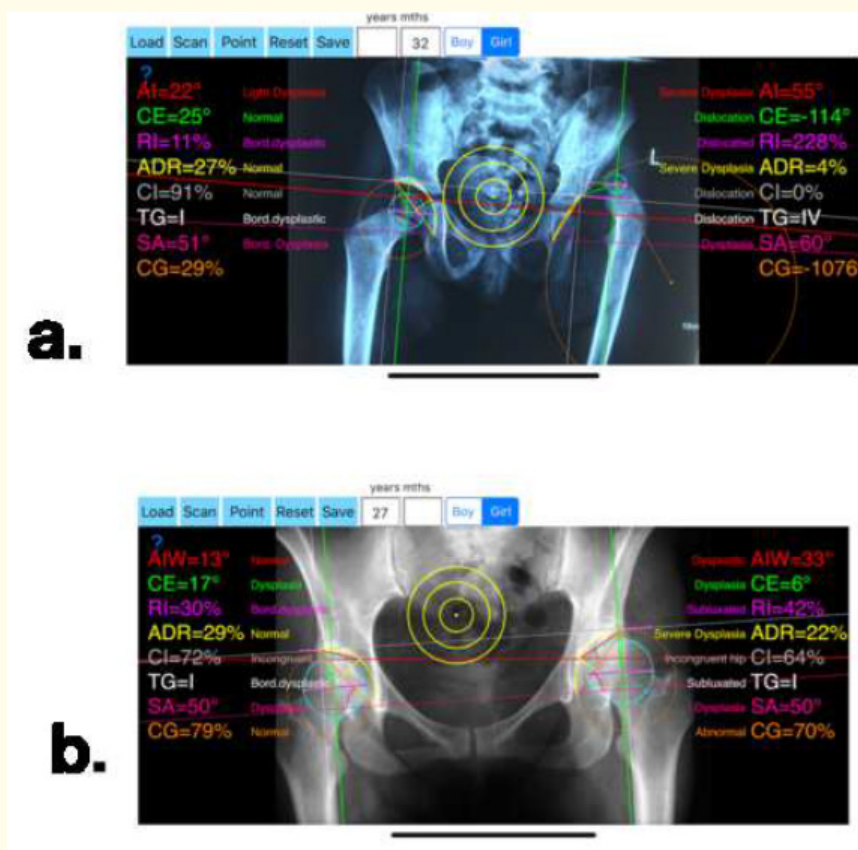


Figure 4: Radiographic Indexes calculated using the HipDysplasiaApp.

The present study showed that the smartphone application presents an excellent and handy tool for evaluating patients in a busy outpatient orthopaedic clinic. It eliminates the necessity of having manual instruments such as goniometers and rulers, and of course the risk of missing some of them when the measurement is needed. Even when using medical imaging technology and software such as PACS (picture archiving and communication system), one also has to digitally draw the lines and calculate all indexes and is obliged to search for normal reference values according to age, gender and side of involvement of the patient.

Given the increasing use and availability of smartphones, an application such as the HipDysplasiaApp could help popularize and trigger awareness about the evaluation of hip dysplasia; a leading cause of premature osteoarthritis [26] for which early diagnosis is of paramount importance. The use of the HipDysplasiaApp as a screening tool is beyond the scope of this article but an interesting use of the application for General Practitioners would be either at schools as a screening tool or for a basic evaluation of every day patients with hip pain. This practice would most likely reduce the high rate of un-necessary referrals to specialists or even highlight patients in need of urgent referrals.

This study proved that the HipDysplasiaApp is a valid application which can be used in the clinical setting for the evaluation of hip dysplasia. Depending on the clinical question related to treatment, planning or outcome of dysplastic hips, the radiographic assessment by specialist orthopaedic surgeons remains the gold standard. Nevertheless, the application is a handy tool to maximise the diagnostic yield from simple pelvic X-rays. The HipDysplasiaApp seems to be a convenient solution to monitor, evaluate, store, handle and compare all the measured data in a rapid way. The authors believe that the application will contribute towards the advancement of orthopaedic care.

Conclusion

The intraobserver and interobserver reliability of the Hip dysplasia App, as well as its validity when compared with the manual measurement, is excellent. The application is valid for clinical evaluation. It is a handy tool for an orthopaedic surgeon. By choosing a few points of measurement on the screen of the application, it calculates the whole range of measurements in seconds. The built-in features can compare the results with a reference database. Furthermore, categorization offers a major helping tool in every-day clinical setting. The values are stored and can be used for later evaluation.

Disclosure

The first author of this study, Nikolaos G Papadimitriou, is the software designer and developer of the HipDysplasiaApp. The application can be purchased on the Apple Store. The rest of the authors declare that they have no conflict of interest.

Bibliography

1. Murphy SB, *et al.* "The prognosis in untreated dysplasia of the hip. A study of radiographic factors that predict the outcome". *Journal of Bone and Joint Surgery-American Volume* 77.7 (1995): 985-989.
2. Pun S. "Hip dysplasia in the young adult caused by residual childhood and adolescent-onset dysplasia". *Current Reviews in Musculoskeletal Medicine* 9.4 (2016): 427-434.
3. Li PL and R Ganz. "Morphologic features of congenital acetabular dysplasia: one in six is retroverted". *Clinical Orthopaedics* 416 (2003): 245-253.
4. Jacobsen S, *et al.* "Hip dysplasia and osteoarthritis: a survey of 4151 subjects from the Osteoarthritis Substudy of the Copenhagen City Heart Study". *Acta Orthopaedica* 76.2 (2005): 149-158.
5. Tönnis D. "Normal values of the hip joint for the evaluation of X-rays in children and adults". *Clinical Orthopaedics and Related Research* 119 (1976): 39-47.
6. Tönnis, D. "Congenital dysplasia and dislocation of the hip in children and adults". Berlin; Heidelberg; New York; London; Paris; Tokyo: Springer (1987).
7. Jacobsen S, *et al.* "Pelvic orientation and assessment of hip dysplasia in adults". *Acta Orthopaedica Scandinavica* 75.6 (2004): 721-729.

8. McClincy MP, et al. "Mild or Borderline Hip Dysplasia: Are We Characterizing Hips With a Lateral Center-Edge Angle Between 18 degrees and 25 degrees Appropriately?" *American Journal of Sports Medicine* 47.1 (2019): 112-122.
9. Novais EN, et al. "Normal Percentile Reference Curves and Correlation of Acetabular Index and Acetabular Depth Ratio in Children". *Journal of Pediatric Orthopaedics* 38.3 (2018): 163-169.
10. Harris NH. "Acetabular growth potential in congenital dislocation of the hip and some factors upon which it may depend". *Clinical Orthopaedics and Related Research* 119 (1976): 99-106.
11. Delaunay S, et al. "Radiographic measurements of dysplastic adult hips". *Skeletal Radiology* 26.2 (1997): 75-81.
12. Tannast M, et al. "What are the radiographic reference values for acetabular under- and over coverage?" *Clinical Orthopaedics and Related Research* 473.4 (2015): 1234-1246.
13. K SI. "Acetabular dysplasia. The acetabular angle". *Journal of Bone and Joint Surgery-British Volume* 43B (1961): 268-272.
14. Tonnis D, et al. "The management of congenital hip luxation with arthrographic control, an individual risk-reducing and time-saving method. I. Choice of method and risk assessment based on arthrographic findings". *Zeitschrift für Orthopädie und ihre Grenzgebiete* 122.1 (1984): 50-61.
15. Harnroongroj T, et al. "Acetabular roof arc angles and anatomic biomechanical superior acetabular weight bearing area". *Indian Journal of Orthopaedics* 48.5 (2014): 484-487.
16. Wang CW, et al. "Comparison of acetabular anterior coverage after Salter osteotomy and Pemberton acetabuloplasty: a long-term followup". *Clinical Orthopaedics and Related Research* 472.3 (2014): 1001-1009.
17. Okano K, et al. "Joint congruency as an indication for rotational acetabular osteotomy". *Clinical Orthopaedics and Related Research* 467.4 (2009): 894-900.
18. Papadimitriou NG. HipDysplasiaApp (2018).
19. Papadimitriou NG. "Functional treatment of Developmental Dysplasia of the Hip with the Papadimitriou Method". General Guidelines - Techniques. first edition. Apple Books - Dr. Nikolaos G. Papadimitriou (2018).
20. Papadimitriou NG, et al. "Late-presenting developmental dysplasia of the hip treated with the modified Hoffmann-Daimler functional method". *Journal of Bone and Joint Surgery-American Volume* 89.6 (2007): 1258-68.
21. Yilmaz G, et al. "Effectiveness of abduction orthosis for the treatment of acetabular dysplasia". *Eklemler Hastalıkları ve Cerrahisi Dergisi* 30.1 (2019): 32-37.
22. Mardam-Bey TH and GD MacEwen. "Congenital hip dislocation after walking age". *Journal of Pediatric Orthopaedics* 2.5 (1982): 478-486.
23. Nikolaos G and Papadimitriou MD P. www.orthopractis.com (2015).
24. Rosner B. "Fundamentals of biostatistics". Boston, MA: Cengage Learning (2016).
25. Gibson PH and MK Benson. "Congenital dislocation of the hip. Review at maturity of 147 hips treated by excision of the limbus and derotation osteotomy". *Journal of Bone and Joint Surgery-British Volume* 64.2 (1982): 169-175.
26. Malvitz TA and SL Weinstein. "Closed reduction for congenital dysplasia of the hip. Functional and radiographic results after an average of thirty years". *Journal of Bone and Joint Surgery-American Volume* 76.12 (1994): 1777-1792.

Volume 10 Issue 10 October 2019

©All rights reserved by Nikolaos G Papadimitriou, et al.