

Old Habits Die Hard: An Unusual Cause of Gastric Bezoar

Keerthana Kesavarapu^{1*}, Anupam Somashekar² and Neilanjan Nandi³

¹Internal Medicine Resident, Hahnemann University Hospital, United States

²Medical Student, Drexel School of Medicine, United States

³Gastroenterology Associate Program Director, Hahnemann University Hospital, United States

***Corresponding Author:** Keerthana Kesavarapu, Internal Medicine Resident, Hahnemann University Hospital, Philadelphia, PA, United States.

Received: October 02, 2017; **Published:** October 10, 2017

Abstract

The present gastric bezoar classification system is very specific and does not permit categorization for plastic or other foreign body etiologies. Here within, we describe the unique case of a 26 y/o male with epigastric bloating, early satiety and anorexia with endoscopy demonstrating a large bezoar obstructing the pylorus that was the aggregate of years of masticating on plastic pen caps (Figure 1,2). The present classification system of bezoars provides 4 categories: phytobezoars (plant fiber), trichobezoars (hair), lactobezoars (milk products) and pharmacobezoars (medications). Although the literature is speckled with case reports of bezoars consisting of various odd materials, no case reports regarding pen caps exists. Furthermore, we propose that this common nervous habit across age ranges may be a useful point of inquiry when approaching clinical histories regarding early satiety and abdominal discomfort in the otherwise healthy patient population. Also, we suggest that an additional bezoar category be developed to accommodate these other foreign material bezoar etiologies. Early diagnosis is important in preventing development of ulceration, bleeding, perforation and obstruction.

Keywords: *Dyspepsia; Bezoar; Reflux; Satiety; Anorexia*

Introduction

The present gastric bezoar classification system is very specific and does not permit categorization for plastic or other foreign body etiologies. Here within, we describe the unique case of a 26-year-old male with epigastric bloating, early satiety and anorexia with endoscopy demonstrating a large bezoar obstructing the pylorus that was the aggregate of years of masticating on plastic pen caps as a nervous habit.

A bezoar is a mass of undigested material found in the gastrointestinal tract. Clinical presentation and complications correlate with their location. Gastric bezoars present with epigastric fullness, bloating, nausea, vomiting and/or signs of gastric outlet obstruction. Bezoars may potentiate localized mucosal ischemic effects from exerting physical pressure upon intestinal mucosa that can ultimately result in ulceration and perforation. The present classification system of bezoars provides 4 categories: phytobezoars (plant fiber), trichobezoars (hair), lactobezoars (milk products) and pharmacobezoars (medications). This system does not allow classification for plastic materials. Previous case reports have commonly demonstrated bezoar formation from persimmons, oranges, coconuts, apples, green beans, sauerkraut, figs, berries, brussels sprout, potato peels, and seeds. The literature is peppered with bezoar case reports consisting of cotton threads, polyurethane, worms, toilet paper, ceiling plaster and furniture cushion foam [1,2]. Notably, no literature exists regarding bezoar formation from chewing and swallowing pen cap material, which is a common habit across a large age range demographic.

Case Report

A 26-year-old male patient presented with a 6-month history of epigastric bloating, anorexia, and early satiety. He denies any abdominal pain, reflux symptoms, nausea/vomiting or weight loss. Examination, laboratory testing and imaging studies are unremarkable. Endoscopy demonstrates a large gastric bezoar extending from the antrum through the pyloric channel and into the duodenal bulb (Figure 1 and 2). Post-endoscopy evaluation reveals the patient has been chewing pen caps most of his life since childhood.

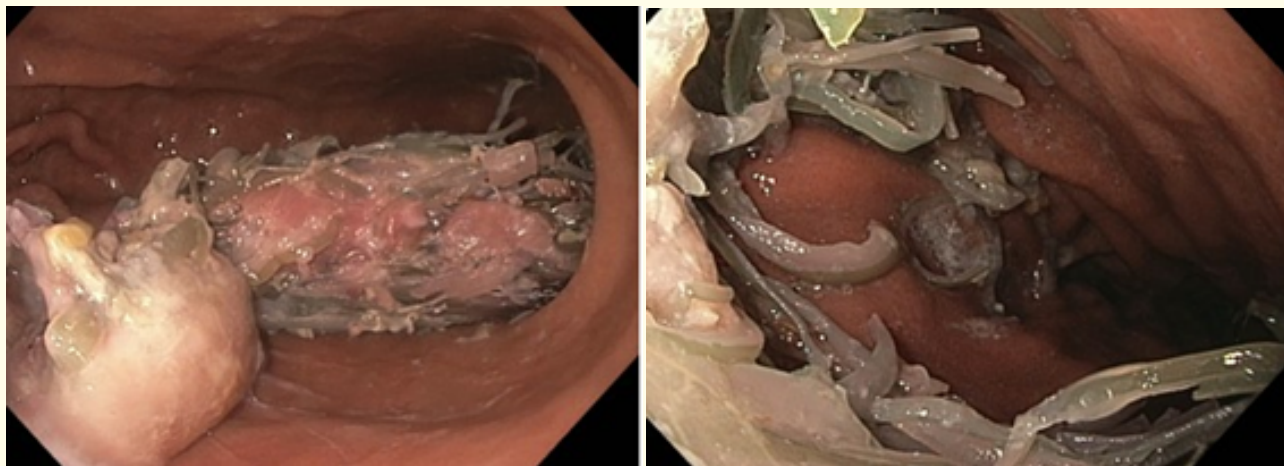


Figure 1 and 2: Picture depicts bezoar with tendrils extending from the antrum of the stomach into the pylorus.

Discussion and Conclusion

To the best of our knowledge this has not been previously reported in the literature. Bezoar formation is a rare disease entity with variable incidence. Literature review of cumulative case reports and case series on Pubmed from 2015 to 2016 shows 52 cases of bezoars. As previously known, much of the reported cases are phytobezoars and trichobezoars. Rare causes of bezoars included plastic material from knitting chairs, ceiling plaster, *Ascaris*, sand, cotton fibers, polyurethane and toilet paper [2-4].

The formation of these bezoars occurs over time when particles become enmeshed with mucous creating a mass. The risk of development becomes more significant in patients with altered gastrointestinal motility. Risk factors include partial gastrectomy with or without partial vagotomy or diabetes mellitus with gastroparesis. Other pre-disposing factors include poor mastication, increased intake of fiber, cystic fibrosis, or psychiatric illnesses. Bezoars mostly originate in the stomach and cause non-specific symptoms like abdominal pain, epigastric bloating/fullness, nausea and vomiting, and anorexia with weight loss. In diagnosing a bezoar, a history and physical should include screening patients for risk factors; however, endoscopy is the test of choice for identifying a bezoar.

In conclusion, we propose that this common habit across age ranges may be a useful point of inquiry when approaching clinical histories regarding early satiety and abdominal discomfort in the otherwise healthy patient population. Also, we suggest that an additional bezoar category be developed to accommodate these other foreign material bezoar etiologies. Early diagnosis is important in preventing development of ulceration, bleeding, perforation and obstruction.

Conflict of Interest

No financial interest or any conflict of interest exists.

Bibliography

1. Chintamani., *et al.* "Cotton Bezoar- a Rare Cause of Intestinal Obstruction: Case Report". *BMC Surgery* 3 (2003): 5.
2. Akbulut Sabiye., *et al.* "Gastric Bezoars". *Przegląd Gastroenterologiczny* 11.1 (2016): 60-61.
3. Gachabayov Mahir., *et al.* "Each Worm to His Taste: Some Prefer to Eat Nettles – a Giant Gastric Phytobezoar". *Clinical Case Reports* 4.7 (2016): 710-711.
4. Yaka Mbarek., *et al.* "Huge Plastic Bezoar: A Rare Cause of Gastrointestinal Obstruction". *The Pan African Medical Journal* 21 (2015): 286.

Volume 3 Issue 6 October 2017

©All rights reserved by Keerthana Kesavarapu., *et al.*