

Using Multidisciplinary Principles in Treatment Planning a Dental Case- A Case Report

Stephanie Aldrich*

General Dentist Fairlawn, Ohio, USA

***Corresponding Author:** Stephanie Aldrich, General Dentist Fairlawn, Ohio, USA.

Received: April 05, 2018; **Published:** May 12, 2018

Abstract

Holistic or comprehensive treatment planning is essential for your long term clientele. Knowing when to utilize dental specialists usually comes with experience of difficult cases. A complete and thorough initial exam is essential to not only evaluating what is needed to treat your patient, but also to help communicate what's needed from your specialists. Gingival contours, biologic width issues, parafunctional conditions, and general periodontal health must be addressed first before treatment begins. You don't want to treatment plan a full mouth rehab case without considering and treating parafunctional habits that will destroy all the porcelain work that you've done. You must also consider the desires of the patient and what their budget warrants. An implant supported hybrid case will be totally different from a composite "patch" job. Wants, needs, and the ability to deliver those desires are very important for complex cases. Here is a case of an 18 year old male who presented to my office at the end of his orthodontic phase of treatment with a missing left maxillary central incisor and a need to create one restoratively using porcelain crowns and reshaping his remaining lateral incisor and canine to mimic a central incisor and lateral incisor. Smile design theories including The Golden Proportion Rule [1] and The Recurring Esthetic Dental Proportion [2] were both considered to help rebuild his smile into an esthetic result.

Keywords: *Comprehensive Treatment Planning; Multidisciplinary Principles in Treatment Planning; Dental Specialists; The Golden Proportion Rule; The Recurring Esthetic Dental Proportion*

Introduction

It still amazes me after 18 years of practicing general dentistry the nuances of our craft. We see thousands of people a year and most of the time, things are "standard" protocol. MOD's, routine crown and bridge, and prophylaxis exams fill our days. I'm not complaining. I love seeing broken teeth that I know I can fix easily, quickly, and profitably. But it's nice to be challenged once in a while when anatomical anomalies come across your chair. It's important as a general dentist to know how to treat a patient to get them to their desired result. Sometimes this is more difficult than you think. Thank goodness we have specialists to help guide us on our journey. I went to Case Western Reserve University School of Dental Medicine. Looking back at my schooling and the last almost two decades of practice, I feel very comfortable in my treatment planning abilities. Case Western was very focused on treating each patient as a complete case. You saw that patient from the initial consultation and did all the work necessary to complete their treatment. So when it came time to go out on my own, I felt very comfortable looking at the forest and knowing how to maneuver around the trees. And knowing when to refer a case out to a specialist has given my patients excellent and predictable results.

Case Report

I was not involved in any of the initial treatment planning phases for this case. I met this 18 year old patient at the end of his orthodontic phase. The patient came in with his mom and wanted to discuss possible solutions to his missing right central incisor (Figure 1 and Figure 2). At age 11, he fell off his swing and fell face first, avulsing #9 and intruding #8 and 10. Emergency brackets were placed to

stabilize his teeth and soon afterwards his orthodontic treatment started. His pediatric dentist placed composite on both his remaining central incisor #8 and his lateral incisor #10 to mimic central incisor widths. Having determined the bone was too thin and damaged to save the space for a future implant, the decision was made to close the central space and use porcelain crowns to rebuild the fractured central incisor, reshape the lateral incisor into a central incisor, and the canine into a lateral incisor leaving the patient's left premolar to mimic the left canine.

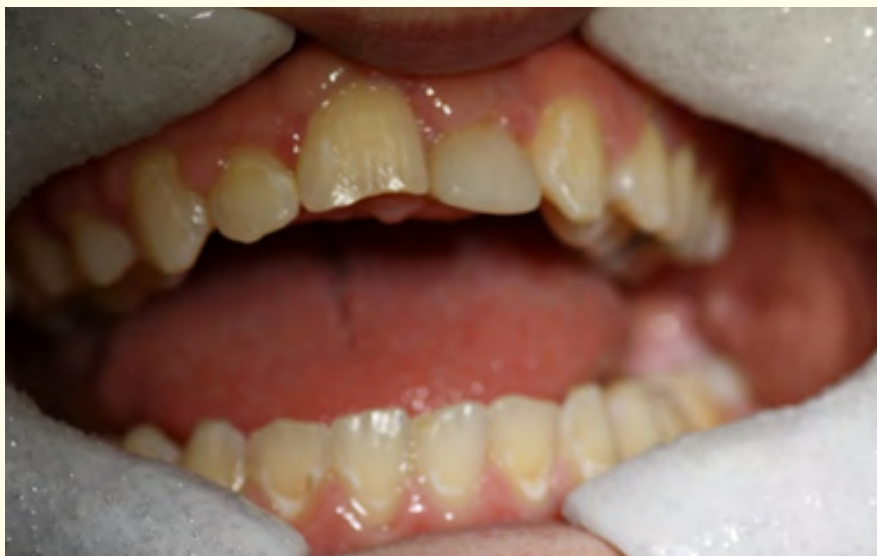

Figure 1: Retracted anterior view showing gingival discrepancies.

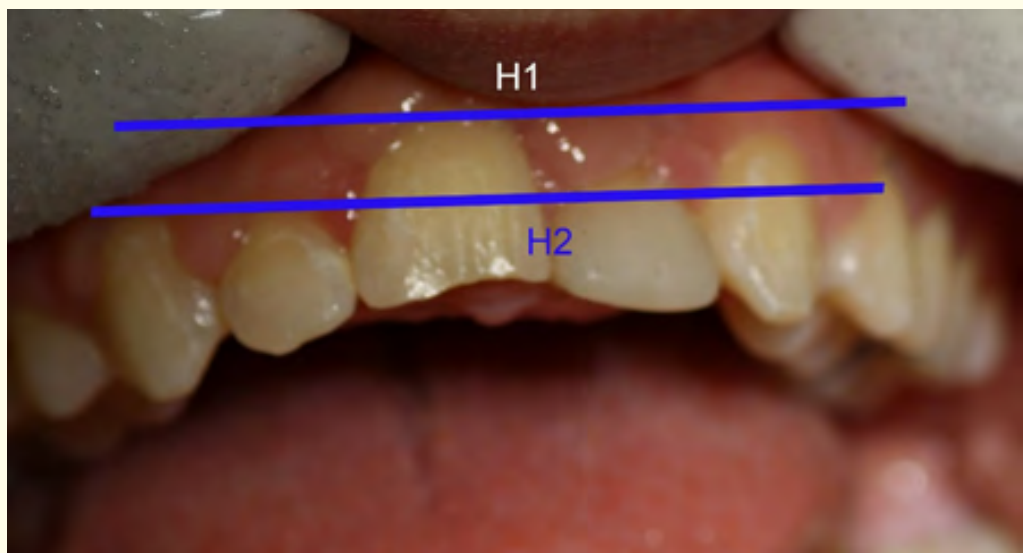


Figure 2: Retracted view showing heights of central incisors and canines prior to periodontal surgery.

The patient came into my office and we started his case with alginate impressions and pored stone models and articulated them for the lab. We sent these models to the lab and had them wax up an ideal proportionate set of crowns. Due to gingival discrepancies, the patient was also referred to the Periodontist to recontour the gingival heights and create the illusion of symmetry for these heights. Once the wax-up was approved and the gingiva healed properly we began his restorative treatment. For this case, I began by anesthetizing the teeth with buccal infiltration using 2% Lidocaine w/1:100,000 epi and 3% Mepivacaine w/o epi. The old composite material was removed and a 701.9 diamond was used to create the chamfer. Genie polyvinylsiloxane (Sultan Healthcare) impressions were taken using light and medium body. Structure Premium (Voco) Bis-acrylic temporary crowns were fabricated using an initial impression and cemented with Temp Advantage (GC America) temporary cement. The impressions were sent to the lab for crown fabrication with the explicate instructions to use the approved wax-up as a guide for the final shape of the porcelain crowns. Two weeks later, the final porcelain crowns were seated. The patient was anesthetized with buccal infiltration using 2% Lidocaine w/1:100,000 epi and 3% Mepivacaine w/o epi. The temporary crowns were removed, the preps were cleaned and the crowns were adjusted and polished. After initial approval from mom and the patient, we proceeded to etch the porcelain crowns internally with 9.6% Hydrofluoric acid (Pulpdent Corp), rinsed them with water, then placed Monobond Plus (IvoclarVivadent) primer and air dried. We then isolated the lips with cheek retractors and etched the dentin with 37% phosphoric acid (Pulpdent Corp), rinsed with water, placed Optibond Solo (Kerr) dental adhesive, light cured for 20 seconds, then cemented the crowns using Maxicem (Kerr) clear cement and light cured for 20 seconds each buccally, incisally, and lingually (Figures 3-6).

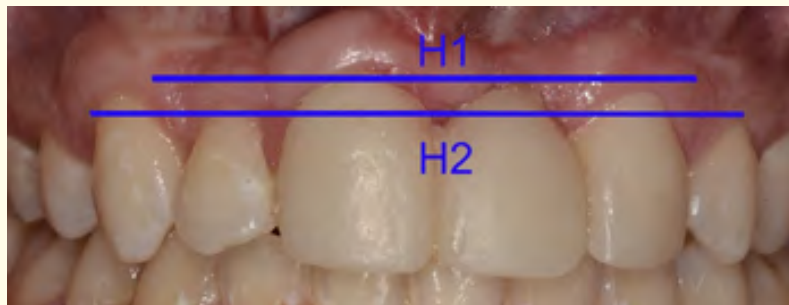

Figure 3: Gingival heights measured after periodontal surgery showing improved symmetry between the centrals through canines.

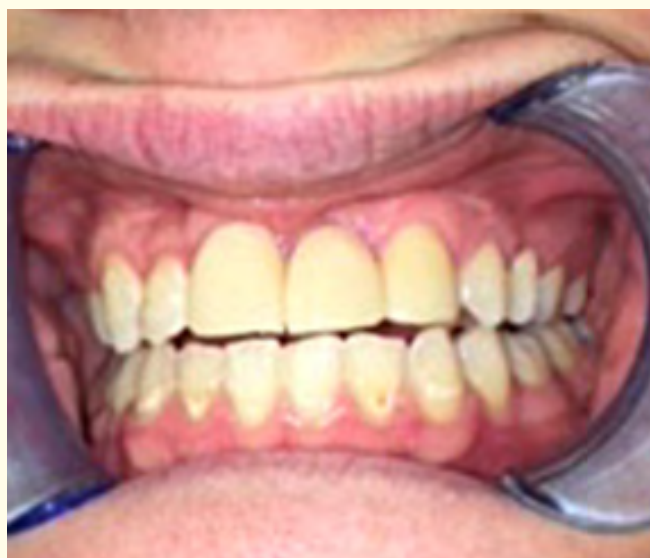

Figure 3: Gingival heights measured after periodontal surgery showing improved symmetry between the centrals through canines.

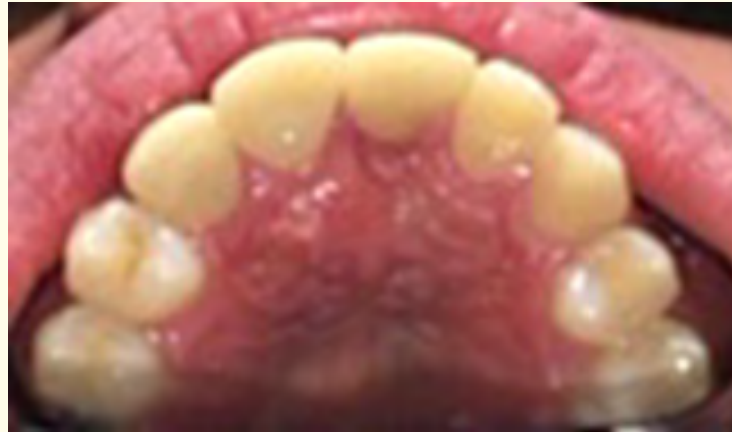

Figure 5: Occlusal view of final crown placement showing gingival contours of the lingual surfaces as well as the arch form generated with the new crowns in place.

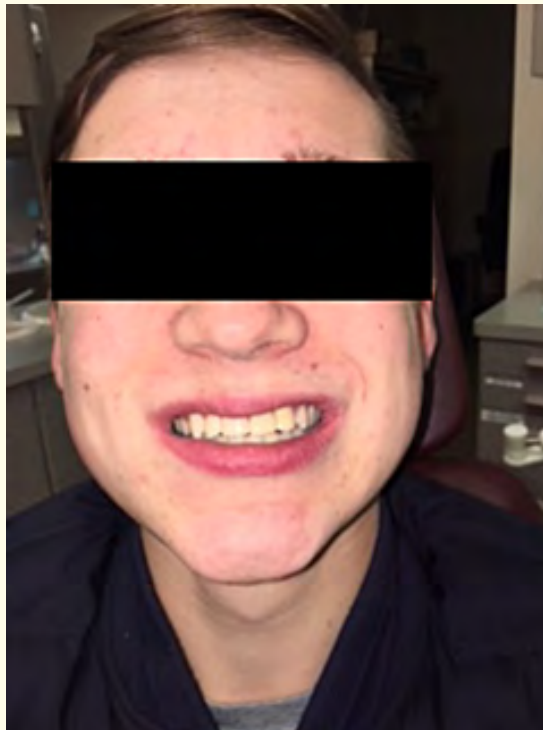

Figure 6: Full face view of final crown placement. Both patient and mom were happy with these results.

Discussion

For this case after impressions and articulated study models were done, I began evaluating the case for treatment. I started with his midline and measured the width of #7, #8, and #11 to see if the lab could mimic the proper shapes/widths of these teeth using the initial composites that the other dentist had done (Figure 1). The Golden proportion rule [1] could not be used in this case because the canine was being used as a lateral incisor and was more prominent not only in width and length but also in gingival height. The Recurring Esthetic Dental Proportion [2] was more subjective in nature and guided me in focusing on the width of the central incisors and then building the smile laterally and posteriorly from there. I only had one central #8 (which was damaged) to deal with so I measured this and matched his other crowns to smooth out any discrepancies. As seen in figure 1, his right lateral incisor was fairly wide and came to a point almost like a canine so masking the canine on the left to make it look like a lateral incisor was not as difficult. In figure 2, I could see that the gingival heights of the right canine and the left premolar (later to mimic the left canine) were fairly close but the remaining central incisor and the left lateral incisor (later to mimic the left central incisor) were not very close. I referred him to the periodontist for gingival recontouring of these anterior teeth. I felt I needed the gingival contours to be reshaped and aligned to their proper heights to make sure we got a pleasing esthetic result. After the gingiva healed, initial impressions and articulated study models were made and sent to the lab for an initial wax-up. The wax-up was approved by the patient and mom and the porcelain crowns were started. EmaxPressed (IvoclarVivadent) lithium disilicate crowns were chosen for this case due to their high translucency and esthetics. Parafunctional concerns were not warranted thus pressed lithium disilicate porcelain could be used without worry of porcelain fracture.

Conclusion

Sometimes you have to throw out the academic proportion models and build a smile subjectively using what Mother Nature presents to you. Teeth misalignment treated with orthodontics, gingival contours treated with periodontics, and width/length proportions treated with esthetic dentistry can help a general dentist generate balance to a patient's mouth. Knowing when and how to use a specialist's skill set can also help create the foundation for this balance.

Acknowledgements

Figure 1 and 2 courtesy of Akron Periodontics and Dental Implantology- Mark Obernesser, DDS MMSc Fairlawn, Ohio, USA.

Bibliography

1. Lombardi RE. "The Principles of Visual Perception and Clinical Application to Denture Esthetics". *Journal of Prosthetic Dentistry* 29.4 (1973): 358-382.
2. Ward DH. "A Study of Dentists' Preferred Maxillary Anterior Tooth Width Proportions: Comparing the Recurring Esthetic Dental Proportion to Other Mathematical and Naturally Occurring Proportions". *Journal of Esthetic Dentistry* 19.6 (2007): 324-339.

Volume 17 Issue 6 June 2018

©All rights reserved by Stephanie Aldrich.