

A Diagnostically Challenging Case of Dedifferentiated Liposarcoma Presenting as a Large Retroperitoneal Mass - Case Report with Review of Literature

Mona Bargotyia¹, Sana Ahuja^{1*}, Payel Das¹ and Tushar Aeron²

¹Department of Pathology, Rajiv Gandhi Super Speciality Hospital, Tahirpur, Delhi, India

²Department of GI Surgery, Rajiv Gandhi Super Speciality Hospital, Tahirpur, Delhi, India

***Corresponding Author:** Sana Ahuja, Department of Pathology, Rajiv Gandhi Super Speciality Hospital, Tahirpur, Delhi, India.

Received: July 09, 2019; **Published:** August 06, 2019

Abstract

Liposarcomas are the commonest soft tissue sarcomas. They are subdivided into 4 histological types- well differentiated, myxoid, pleomorphic and dedifferentiated. Dedifferentiated liposarcomas are most commonly found in the retroperitoneum. Patients usually present with complaints of abdominal distension. Radical resection is the treatment of choice. Extensive sampling and thorough histological examination for lipoblasts is mandatory in any undifferentiated pleomorphic sarcoma arising from the retroperitoneum to exclude the possibility of a dedifferentiated liposarcoma. It is important to differentiate dedifferentiated liposarcoma from other retroperitoneal sarcomas as their prognosis is better than the rest. Herein, we are presenting a case of dedifferentiated liposarcoma in a 61 year old with complaints of progressive abdominal discomfort and distension for 8 months.

Keywords: *Liposarcoma; Dedifferentiated; Lipomatous; Retroperitoneum*

Introduction

Sarcomas are considered rare neoplasms representing less than 1% of all malignancies. Among them, liposarcomas constitute 15 - 20% of all malignant mesenchymal lesions, therefore making them the commonest soft tissue sarcomas [1]. According to WHO classification (2013), they are divided into five subtypes: Atypical lipomatous neoplasm/Well differentiated Liposarcoma, Myxoid/Round cell tumour, Dedifferentiated, Pleomorphic sarcoma or Liposarcoma not otherwise specified [2]. Another classification according to histopathological features divided this entity into 4 groups - well differentiated, myxoid, pleomorphic and dedifferentiated. Well differentiated and myxoid liposarcomas are low grade tumours with an indolent clinical course while dedifferentiated, round cell and pleomorphic liposarcomas are high grade aggressive tumours with metastatic potential [3]. The concept of dedifferentiated liposarcoma was described by Evans in 1979 as a dimorphic tumour with areas of well differentiated liposarcoma juxtaposed with high grade spindle cell areas [4]. It is seen most frequently in middle aged and older adults [5]. The most common site of origin of dedifferentiated liposarcoma is retroperitoneum. However, they can arise in the extremities [6,7], trunk [8] and rarely head and neck [9].

Case Report

A 61year old man presented to the Department of GI Surgery with abdominal discomfort along with progressive abdominal distension for 8 months. Contrast enhanced computed tomography showed presence of a large retroperitoneal mass on the left side displacing the left kidney along with left sided hydronephrosis (Figure 1A and 1B). The past medical history of the patient was not significant. The routine laboratory investigations were within normal limits with mildly compromised renal function tests.

Per-operative findings stated a solid cystic lesion in the retroperitoneum encasing the left ureter. Gross examination of the tumour showed a partially encapsulated globular grey white to grey brown specimen measuring 20 x 18 x 7 cm. Outer surface was bosselated

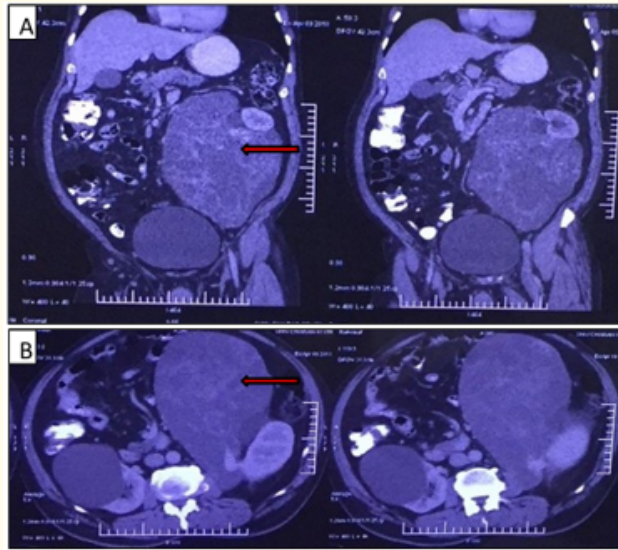


Figure 1A and 1B : CECT whole abdomen showing presence of a large retroperitoneal mass displacing the left kidney.

with presence of numerous dilated and congested blood vessels. Capsular breach was also identified in few areas. Cut surface was firm to fleshy with variegated solid cystic appearance (Figure 2A and 2B). The cystic spaces were filled with gelatinous greenish coloured mucoïd material (Figure 2C and 2D). Areas of necrosis and haemorrhage were also identified.

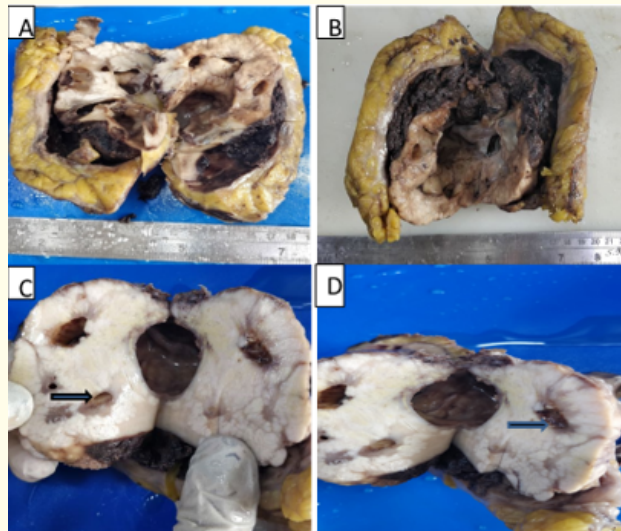


Figure 2 : Gross Findings 2A-2B Partially encapsulated globular greyish white to greyish brown soft tissue specimen. Cut surface is firm and fleshy showing variegated appearance with grey white solid and cystic areas. 2C-D: Cystic spaces filled with gelatinous mucoïd material.

The histopathological examination showed a biphasic tumour composed of lipomatous component and high grade pleomorphic undifferentiated tumour (Figure 3A). The lipomatous areas revealed mature adipocytes separated by fibrovascular septae. Few pleomorphic multivacuolated lipoblasts with bizarre hyperchromatic and scalloped nuclei also identified (Figure 3B-3D). The high grade areas showed tumour cells arranged in fascicles and storiform pattern with whorling noted at a few places (Figure 3E and 3F). The tumour cells were pleomorphic, round to oval with vesicular chromatin, prominent nucleoli and eosinophilic cytoplasm. Many multivacuolated tumour giant cells were noted. Large areas of haemorrhage and necrosis with many dilated and congested blood vessels seen. Numerous mitotic figures including many atypical forms noted.

The final report was dispatched as Malignant Dedifferentiated Liposarcoma, Grade 3 (TNM stage: pT4N0M0). The patient was discharged 15 days after surgery and the post-operative follow up is unremarkable till date.

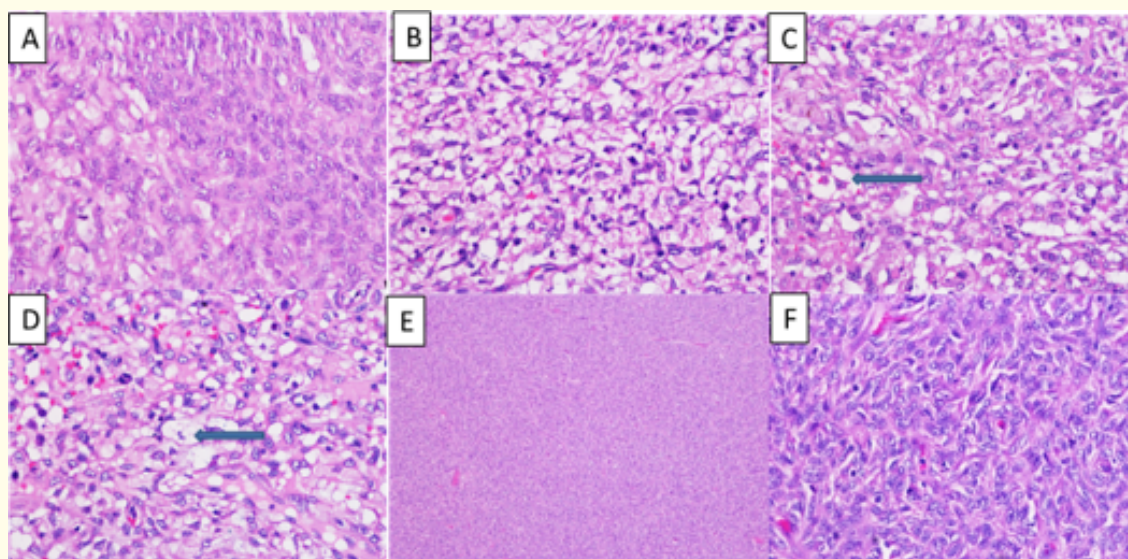


Figure 3: Histopathological findings. 3A: A biphasic tumour composed of lipomatous component and high grade pleomorphic undifferentiated sarcoma.

3B-3D: High power view showing lipomatous tumour composed of mature adipocytes of various sizes.

Few pleomorphic multivacuolated lipoblast with bizzare hyperchromatic nuclei seen. 3E-3F:

Low power and high power view of pleomorphic undifferentiated sarcoma cells arranged in storiform and fascicles pattern showing whorling at few places.

Discussion

Liposarcomas are the commonest soft tissue sarcomas [1]. They are classified into 4 categories- well differentiated liposarcoma/atypical lipomatous tumours, myxoid, pleomorphic and dedifferentiated. Most common type is myxoid liposarcoma (approximately 50% of all liposarcomas) followed by well differentiated liposarcoma. Dedifferentiated liposarcomas occur in upto 10% of well differentiated liposarcoma.

Well differentiated liposarcomas can arise in the extremities or retroperitoneum. They are more common in the 5th to 7th decade of life [10]. Incidence of dedifferentiation of these tumours at any site is around 10% [10]; however it increases in neoplasms situated in deeper locations like retroperitoneum [4].

Dedifferentiated liposarcoma presents most commonly in the 6th to 8th decade with equal gender distribution [5]. Retroperitoneum is the most frequent site such that undifferentiated pleomorphic sarcomas arising from the retroperitoneum are thought to represent dedifferentiated liposarcomas [11]. Other sites include extremities [6,7], trunk [8], head and neck [9]. Majority of dedifferentiated liposarcomas (approximately 90%) arise de novo whereas the remainder arise in previous well differentiated liposarcomas [13]. They usually present as painless masses with a history of slow increase in size leading to abdominal distension or symptoms from compression effect on other surrounding organs.

Dedifferentiated liposarcomas is a high grade sarcoma with aggressive behavior and increased risk of recurrence. This entity is mostly time dependent rather than site dependent phenomenon. Risk of local recurrence is around 40%, risk of metastasis ranges from 15 to 30% and 5 year survival rate is 28% [1,15]. Metastasis of dedifferentiated liposarcomas could be within the retroperitoneum or to distant sites like the brain, liver, bone or lungs. Most important adverse prognostic factor is location in the retroperitoneum as it is associated with worse survival in comparison to other locations [13].

Dedifferentiated liposarcomas are large, multinodular with grey white to yellowish cut surface with variegated appearance. They may contain discrete, solid, often tan-grey non-lipomatous (dedifferentiated) areas. Dedifferentiated areas often show necrosis. Usually there is an abrupt transition from the well differentiated liposarcoma to dedifferentiated liposarcomas [14]. Dedifferentiated areas most frequently show 'MFH'-like pleomorphic sarcoma or intermediate to high grade myxofibrosarcoma. They typically are highly cellular with marked pleomorphism with cells arranged in a fascicular or storiform pattern with a collagenous or myxoid stroma. Rarely, dedifferentiated liposarcomas could be low grade with bland histologic features [15].

Heterologous differentiation towards osteoid, chondroid or myoid differentiation may be seen in about 5% cases [16]. Retroperitoneal liposarcomas with rhabdomyoblastic differentiation are associated with worst outcome [17]. The extent of dedifferentiated areas does not seem to predict the outcome. Paradoxically, despite being a high grade tumour, it exhibits a less aggressive clinical course, although the basis for this difference is still unknown. It could be attributed to relative absence of complex karyotypic aberrations and integrity of the TP53 [2].

In table 1, we compared clinicopathological parameters of our case with other studies.

Dedifferentiated liposarcomas have a varied immunohistochemical profile with variable CD34 expression with focal SMA positivity [29]. Combined use of CDK4, MDM2 and p16 is useful to differentiate well differentiated liposarcoma/ dedifferentiated liposarcomas from other lipogenic tumours. Among these, p16 is most sensitive and specific marker for well differentiated liposarcoma/dedifferentiated liposarcomas while MDM2 is the least [30].

Genetics of dedifferentiated liposarcomas include amplification of chromosome 12q13-15 which includes genes like CDK4, MDM2 and HMGA2 seen at locus 12q14.3 [31]. A significant increase in the level of both MDM2 overexpression and amplification in the high-grade areas has been related with tumor progression [32,33].

The treatment guidelines include radical resection with removal of contiguous viscera to achieve complete tumour clearance. Impact of non-surgical therapy is yet to be clearly defined.

Sr. no.	Name of authors	No. of cases	Most common clinical presentation	Location	Age	Gender	Heterologous elements
1.	McCormick, <i>et al.</i> (1994) [15]	32	Abdominal pain or slow growing mass depending on location	Retroperitoneum: 15 (47%) Extremities: 6 (19%) Paratesticular: 4 (13%) Peritoneal: 3 (9%) Trunk: 2 (6%) Buttock: 1 (3%) Larynx: 1(3%)	Median: 67	Male: 20 (62%) Female: 12 (38%)	-
2.	Moyon, <i>et al.</i> (2018) [18]	1	Abdominal mass	Retroperitoneum	34	Female	-
3.	Trombatore, <i>et al.</i> (2016) [19]	1	Abdominal discomfort	Retroperitoneum	68	Female	Osteosarcomatous component
4.	Salata, <i>et al.</i> (2016) [8]	1	Chest pain	Diaphragm	26	Female	Chondroid component
5.	Koroly, <i>et al.</i> (2016) [20]	1	Chest pain	Diaphragm	67	Female	-
6.	Luo, <i>et al.</i> (2018) [21]	61	Abdominal mass	Retroperitoneum	Median: 51	Male: 30 (49%) Female: 31 (51%)	-
7.	Kim, <i>et al.</i> (2010) [22]	1	Abdominal mass	Retroperitoneum	51	Male	-
8.	Agrawal, <i>et al.</i> (2015) [23]	1	Slow growing mass	Buttock	39	Male	Chondrosarcomatous differentiation
9.	Jagtap, <i>et al.</i> (2013) [24]	1	Swelling in left thigh	Thigh	60	Female	Fibrosarcomatous differentiation
10.	Naniwadekar, <i>et al.</i> (2016) [25]	1	Swelling in the dorsum of foot	Foot	80	Female	-
11.	Sinhasan, <i>et al.</i> (2016) [26]	1	Swelling in thigh	Thigh	30	Male	-
12.	Wang, <i>et al.</i> (2012) [9]	1	Painless mass in right neck	Neck	20	Female	-
13.	Andrea, <i>et al.</i> (2018) [27]	1	Swelling in upper eyelid	Orbit	47	Male	-
14.	Nimura, <i>et al.</i> (2017) [28]	1	Firm non tender mass	Oral floor	69	Male	-
15.	Our case	1	Abdominal distension	Retroperitoneum	61	Male	-

Table 1: Clinicopathological parameters of other studies compared with our case.

Conclusion

The importance of diagnosing a dedifferentiated liposarcoma and differentiating it from other sarcomas in the retroperitoneum lies in the fact that their prognosis is better than the other undifferentiated pleomorphic sarcomas. Extensive sampling and thorough histological examination for lipoblasts is mandatory in any undifferentiated pleomorphic sarcoma arising from the retroperitoneum to exclude the possibility of a dedifferentiated liposarcoma.

Bibliography

1. Dei Tos AP. "Liposarcoma: new entities and evolving concepts". *Annals of Diagnostic Pathology* 4.4 (2000): 252-266.
2. Fletcher CD, et al. "WHO classification of tumours of soft tissue and bone". World Health Organisation. Lyon, France (2013).
3. Cargo AM and Singer S. "Clinical and Molecular Approaches to Well differentiated and Dedifferentiated Liposarcoma". *Current Opinion in Oncology* 23.4 (2011): 373-378.
4. Evans HL. "Liposarcoma: a study of 55 cases with a reassessment of its classification". *American Journal of Surgical Pathology* 3.6 (1979): 507-523.
5. Okamoto S, et al. "Dedifferentiated liposarcoma with rhabdomyoblastic differentiation in an 8-yearold girl". *Pathology - Research and Practice* 206.3 (2010): 191-196.
6. Kransdorf MJ, et al. "Dedifferentiated liposarcoma of the extremities: imaging findings in four patients". *American Journal of Roentgenology* 161.1 (1993): 127-130.
7. Yoon RS, et al. "Dedifferentiated liposarcoma of thigh with chondrosarcomatous dedifferentiated component". *American Journal of Orthopedics* 39.11 (2010): E114-E118.
8. Sakata S, et al. "Primary Diaphragmatic Dedifferentiated Liposarcoma in a Young Female Patient after Delivery". *Case Reports in Oncological Medicine* (2016): 4042719.
9. Wang Y and Shi H. "Dedifferentiated Liposarcoma of the Neck: CT Findings". *American Journal of Neuroradiology* 33.1 (2012) E4-E6.
10. Evans HL, et al. "Atypical lipoma, atypical intramuscular lipoma, and well differentiated retroperitoneal liposarcoma: a reappraisal of 30 cases formerly classified as well differentiated liposarcoma". *Cancer* 43.2 (1979): 574-584.
11. Dei Tos AP. "Dedifferentiated liposarcoma". In: Fletcher CDM, Bridge JA, Hogendoorn PCW, Mertens F, eds. WHO Classification of Tumours of Soft Tissue and Bone. Fourth edition. Lyon, France: IARC (2013): 37-38.
12. Coindre JM, et al. "Most malignant fibrous histiocytomas developed in the retroperitoneum are dedifferentiated liposarcomas: a review of 25 cases initially diagnosed as malignant fibrous histiocytoma". *Modern Pathology* 16.3 (2003): 256-262.
13. Henricks WH, et al. "Dedifferentiated liposarcoma: a clinicopathological analysis of 155 cases with a proposal for an expanded definition of dedifferentiation". *American Journal of Surgical Pathology* 21.3 (1997): 271-821.
14. Fisher C. "Liposarcoma". In: Fisher C, Montgomery E, Thway K, eds. Biopsy Interpretation of Soft Tissue Tumors. Philadelphia, PA: Wolters Kluwer (2010): 363-380.
15. McCormick D, et al. "Dedifferentiated liposarcoma. Clinicopathologic analysis of 32 cases suggesting a better prognostic subgroup among pleomorphic sarcomas". *American Journal of Surgical Pathology* 18.12 (1994): 1213-1223.
16. Evans HL, et al. "Heterologous elements in the dedifferentiated component of dedifferentiated liposarcoma". *American Journal of Surgical Pathology* 18.11 (1994): 1150-1157.
17. Gronchi A, et al. "Myogenic differentiation and histologic grading are major prognostic determinants in retroperitoneal liposarcoma". *American Journal of Surgical Pathology* 39.3 (2015): 383-393.

18. Moyon FX, et al. "Massive retroperitoneal dedifferentiated liposarcoma in a young patient". *Journal of Surgical Case Reports* 10 (2018): rjy272.
19. Trombatore C, et al. "Dedifferentiated Liposarcoma of Retroperitoneum With Extensive Osteosarcomatous Component". *International Surgery* 101.5 (2016): 217-221.
20. Virágh KA, et al. "Primary liposarcoma of the diaphragm: a rare intra-abdominal mass". *Radiology Case Reports* 12.1 (2016): 136-140.
21. Luo P, et al. "Retroperitoneal dedifferentiated liposarcoma: Analysis of 61 cases from a large institution". *Journal of Cancer* 9.21 (2018): 3831-3838.
22. Kim ES, et al. "Dedifferentiated liposarcoma of the retroperitoneum". *Cancer Research and Treatment* 42.1 (2010): 57-60.
23. Agrawal T, et al. "A Rare Case of Dedifferentiated Liposarcoma with Chondrosarcomatous Dedifferentiation". *Journal of Evolution of Medical and Dental Sciences* 4.48 (2015): 8425-8429.
24. Jagtap SV, et al. "Huge dedifferentiated liposarcoma of the left thigh with a high grade fibrosarcomatous differentiation and a local recurrence". *Journal of Clinical and Diagnostic Research* 7.3 (2013): 553-556.
25. Naniwadekar RG, et al. "Dedifferentiated liposarcoma of foot - A case report". *Journal of Evolution of Medical and Dental Sciences* 5.87 (2016): 6526-6528.
26. Sinhasan SP, et al. "Dedifferentiated liposarcoma of thigh: Tumor with monster cells". *Clinical Cancer Investigation Journal* 5.2 (2016): 188-192.
27. Andrea T, et al. "Primary dedifferentiated liposarcoma of the orbit, a rare entity: Case report and review of literature". *Saudi Journal of Ophthalmology* (2019).
28. Nimura F, et al. "Dedifferentiated liposarcoma of the oral floor: A case study and literature review of 50 cases of head and neck neoplasm". *Oncology Letters* 15.5 (2018): 7681-7688.
29. Suster S and Fisher C. "Immunoreactivity for the human hematopoietic progenitor cell antigen (CD34) in lipomatous tumors". *American Journal of Surgical Pathology* 21.2 (1997): 195-200.
30. Thway K, et al. "Diagnostic Utility of p16, CDK4, and MDM2 as an immunohistochemical panel in distinguishing well-differentiated and dedifferentiated liposarcomas from other adipocytic tumors". *American Journal of Surgical Pathology* 36.3 (2012): 462-469.
31. Italiano A, et al. "HMGA2 is the partner of MDM2 in well differentiated and dedifferentiated liposarcomas whereas CDK4 belongs to a distinct inconsistent amplicon". *International Journal of Cancer* 122.10 (2008): 2233-2241.
32. Dei Tos AP, et al. "Molecular abnormalities of the p53 pathway in dedifferentiated liposarcoma". *Journal of Pathology* 181.1 (1997): 8-13.
33. Nakayama T, et al. "mdm2 gene amplification in bone and soft tissue tumours: Association with tumour progression in differentiated adipose tissue tumours". *International Journal of Cancer* 64.5 (1995): 342-346.

Volume 2 Issue 6 September 2019

©All rights reserved by Sana Ahuja, et al.